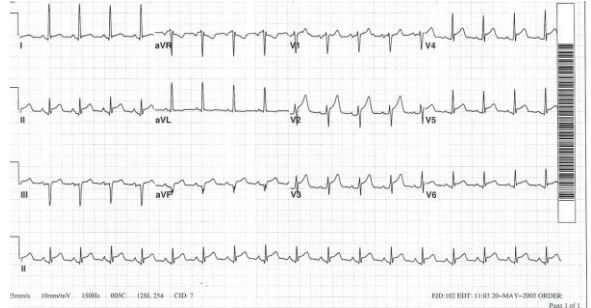


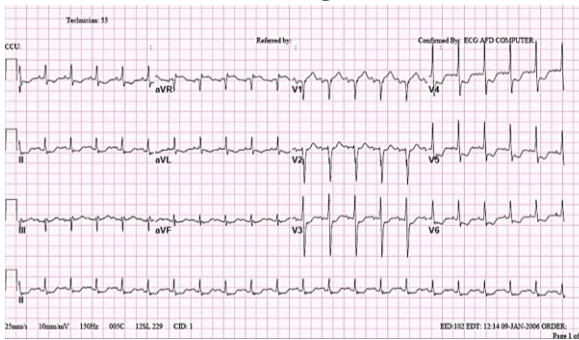
12 kanaals ECG

Bijbehorende PPT

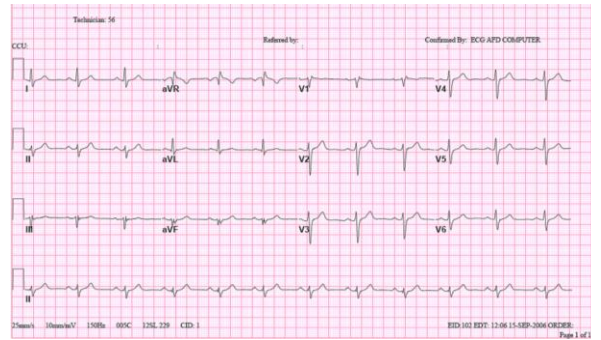
ECG met st elevatie VW, OW, LW



ECG met st-depressie in vrijwel alle afleidingen

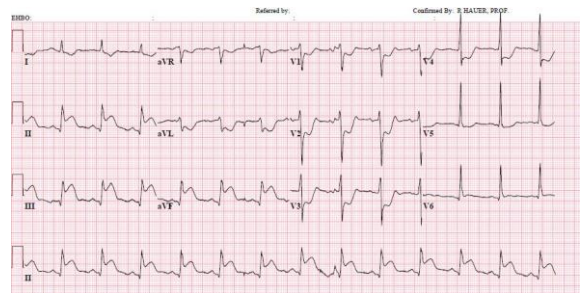
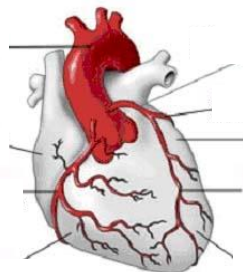


Gewoon SR

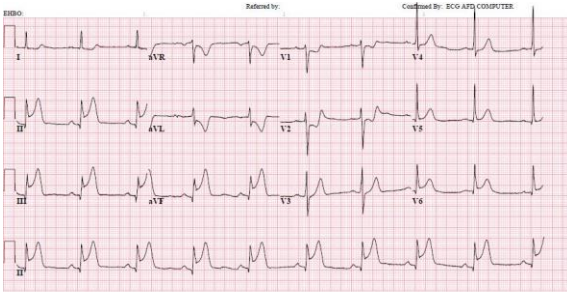


OWI, st elevatie II, III, aVF, reciproke ST depressie I, aVL, V1- V4

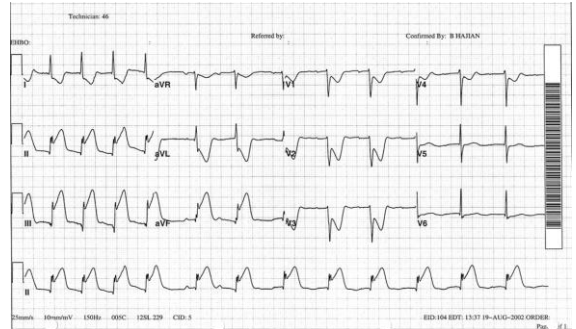
- Linker coronair arterie/hoofdstam
- Aortaboog
- Ramus circumflex
- Linker ventrikel
- Rechter coronair arterie
- Linker atrium
- Rechter ventrikel
- Left anterior descendus
- Rechter atrium



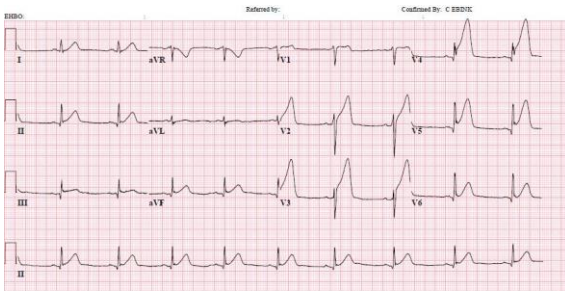
Inferolateraal infarct, ST elevatie II, III, aVF, V5, V6, reciproke ST depressie V1, V2, aVL



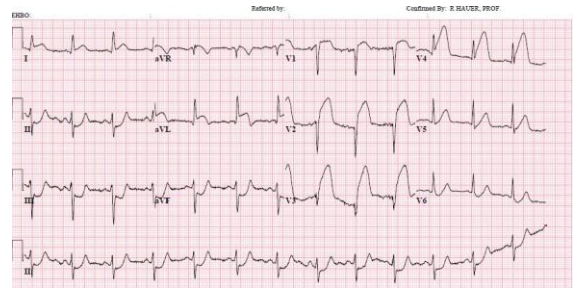
OWI, ST elevatie II, III, aVF. Reciproke ST depressie: I, aVL, V1-V4



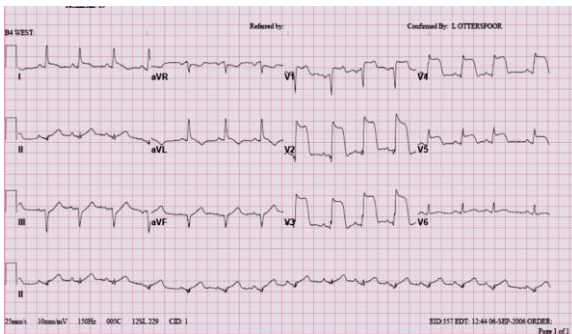
Acuut VWI, spitse t-toppen en elevatie V2-V6. Ook een klein beetje ST elevatie II, III, aVF. Geen reciproke depressie te zien. Waarschijnlijk groot infarct mogelijk zowel LAD als RCX (VW en OW)



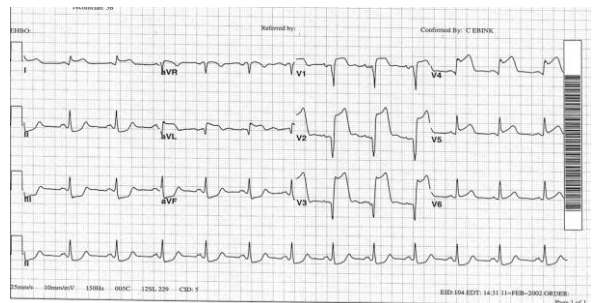
Anterolateraal infarct. ST elevatie I, aVL, V1-V4. Reciproke depressie: II, III, aVF



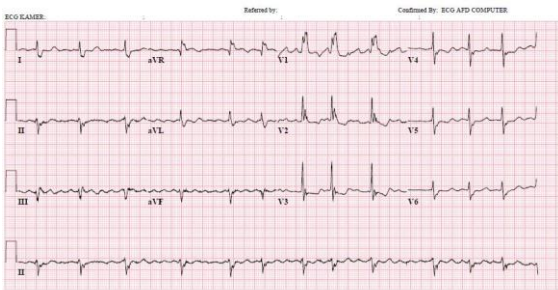
Anterolateraal infarct. ST elevatie: I, aVL, V1-V5. Geen reciproke depressie te zien (zie je ook niet altijd bij een VWI)



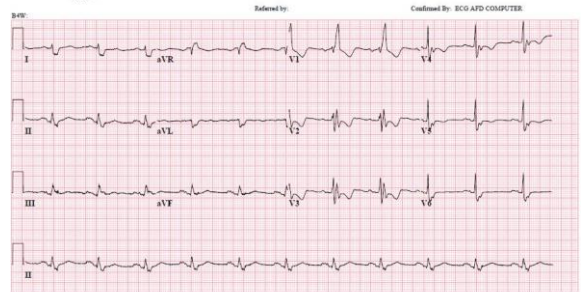
Anterolateraal infarct. ST elevatie I, aVL V1-V5. Reciproke depressie: II, III, aVF



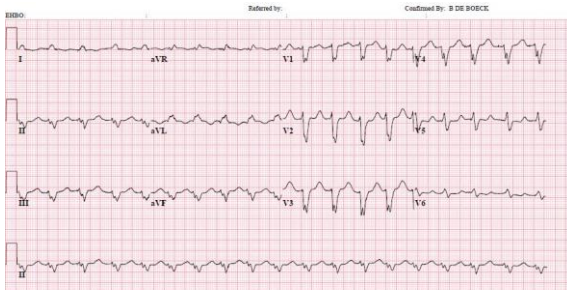
RBTB, Breed QRS complex, Overwegend positief in V1, rsR' in V1 en diepe brede s in I, aVL, V6



RBTB: Breed QRS complex, overwegend positief V1, RsR'V1. Diepe brede S V6, I en aVL



LBTB. Breed QRS complex Overwegend negatief V1. RsR' I, aVL



LBTB, Breed QRS complex, Overwegend negatief V1, RsR' I, aVL, V5, V6

