

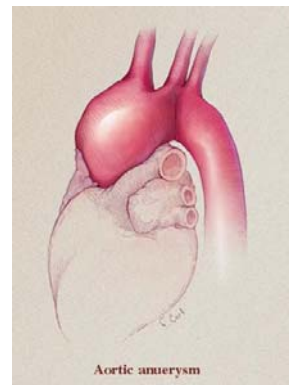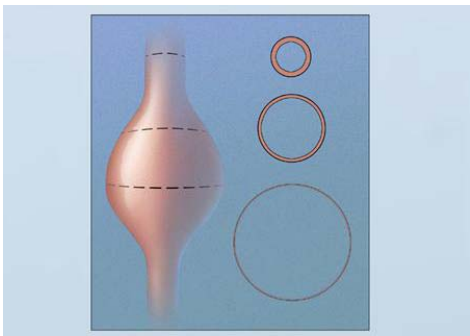
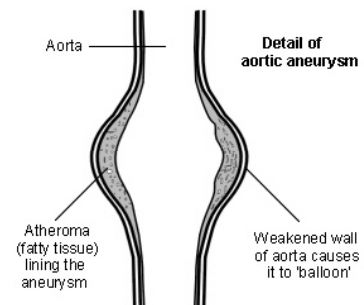
AORTA-CHIRURGIE

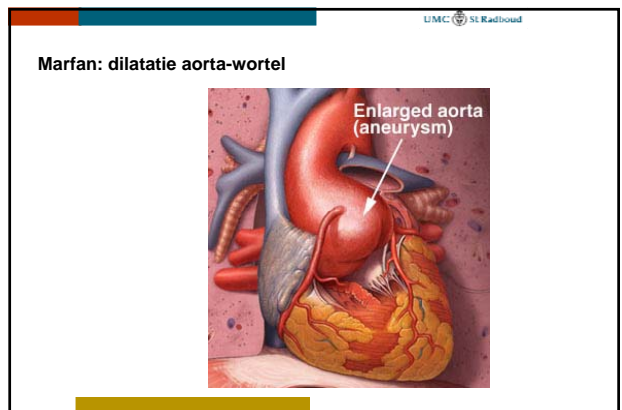
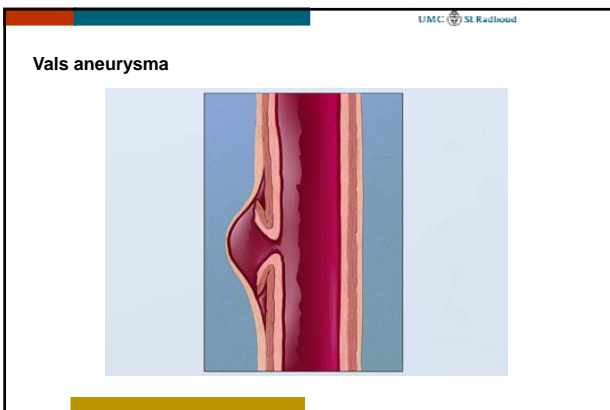
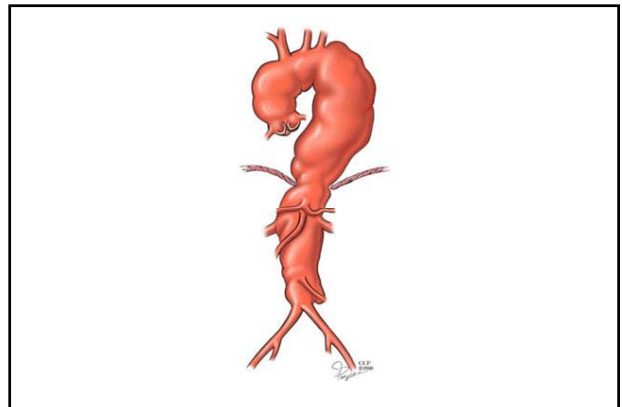
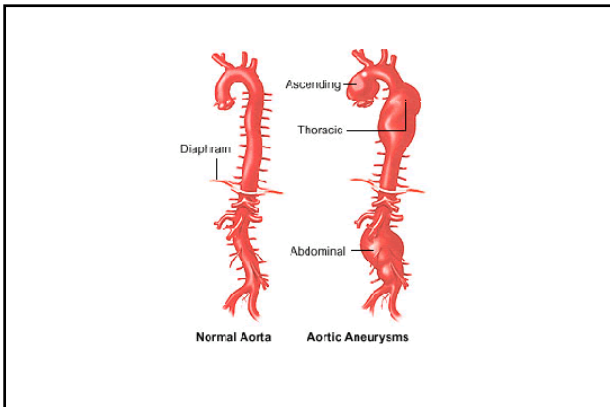
H.van Wetten
 Cardio-thoracale chirurgie

AORTA-ANEURYSMA

Aneurysma

- Verwijding van alle lagen : intima, media en adventitia
- Toename van diameter geeft toename van wandspanning
 - Wet van Laplace : $T = P \times r$
- Oorzaken
 - Bindweefselafwijkingen: Marfan e.d., medianecrose
 - Atherosclerose
 - Post-stenotisch
 - Na dissectie
- Risico: dissectie, ruptuur





UMC St Radboud

Aneurysma : indicaties interventie

- Aorta ascendens : > 5 cm diameter (Marfan > 4.5 cm)
- (snelle) progressie diameter
- "scheurfamilie": in familie personen met dissecties/acute dood

UMC St Radboud

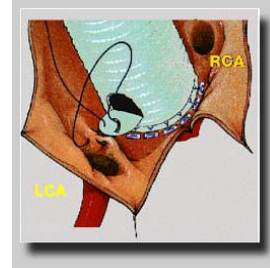
Aneurysma : interventie

- Stent
 - Aorta descendens/abdominaal
- Operatie
 - Verkleinen diameter (reven)
 - Vervanging:
 - Supracoronaire ascendensvervanging
 - Klepsparende wortelvervanging : Yacoub, David
 - Klepvervanging : Bentall
 - Boog : reïmplantatie halsvaten

Klephoudende graft: Bentall-procedure



Bentall-procedure



Bentall-procedure

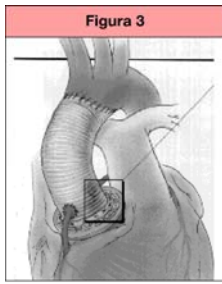
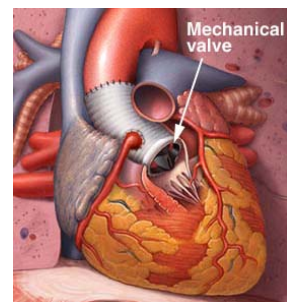
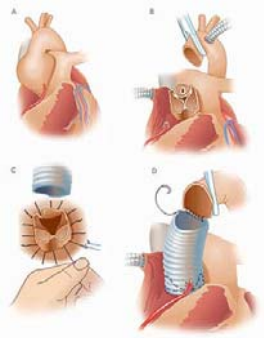


Figura 3. Operació de Bentall-De Bono amb la modificació de la implantació de les coronàries amb tècnica de botó.

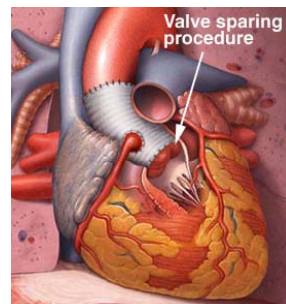
Bentall-procedure

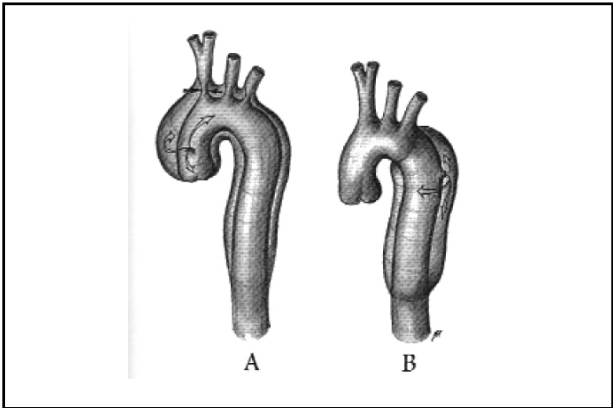
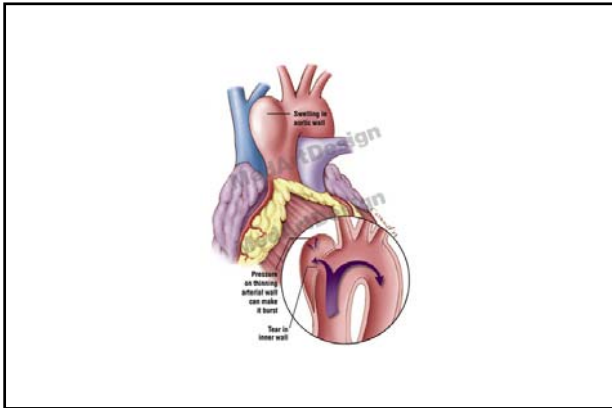
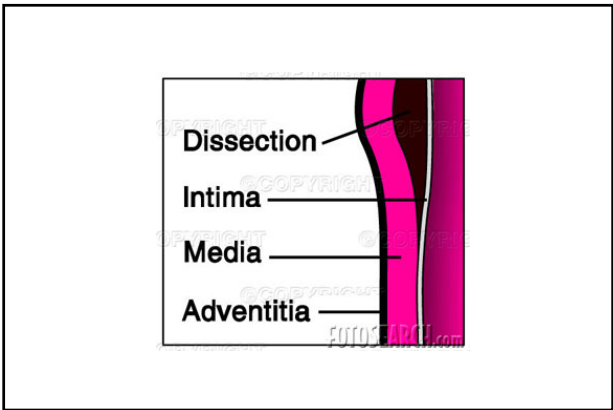
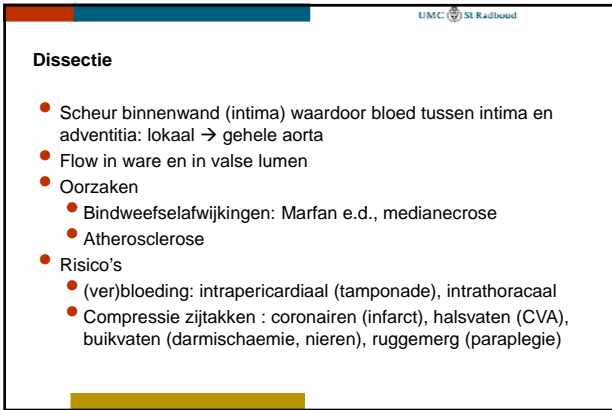
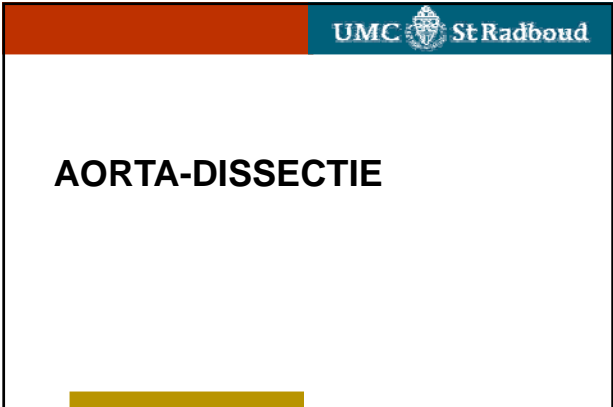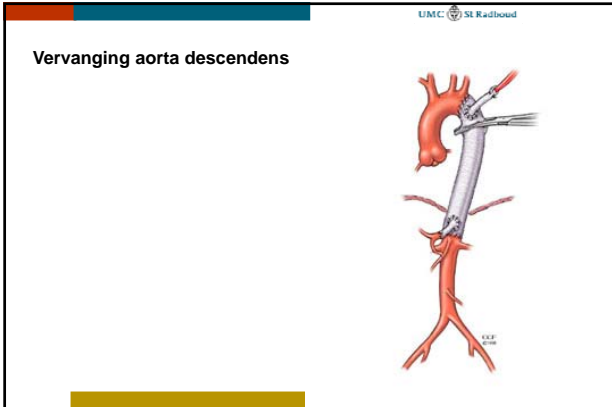


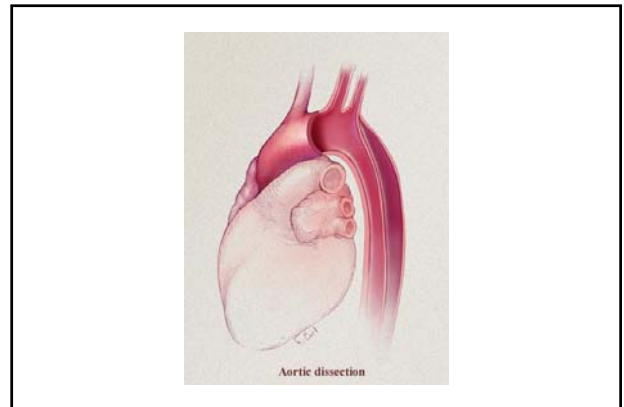
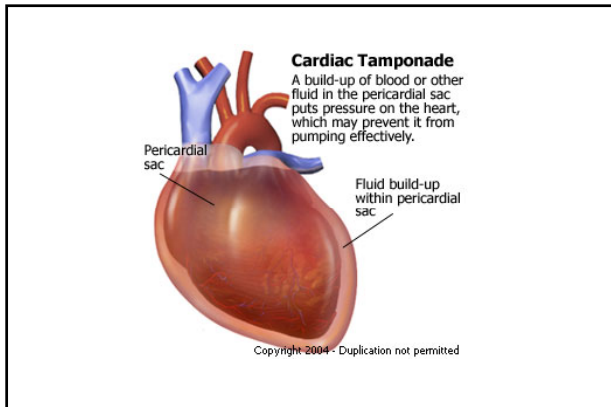
Klepparende aortawortel-
vervanging (David)



Valve sparing
procedure







UMC St Radboud

Dissectie : indicaties interventie

- Aorta ascendens : i.p. spoedindicatie operatie ("Golden Hour")
- Aorta-boog : idem
- Aorta descendens :
 - i.p. conservatief : bedrust, bloeddrukverlaging (B-blokker)
 - Interventie :
 - Blijvende klachten
 - Uitvalsverschijnselen: nieren, darmen, benen

UMC St Radboud

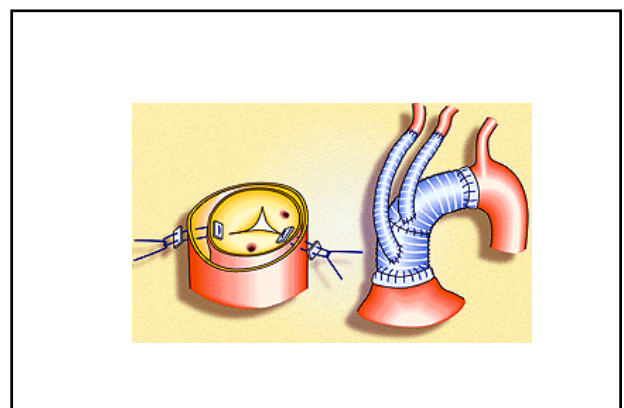
Dissectie : interventie

- Stent
 - Aorta desendens/abdominaal
- Operatie
 - Verkleinen diameter (reven)
 - Vervanging: reimplantatie coronairen
 - Klepsparend : Yacoub, David
 - Klepvervanging : Bentall
 - Boog : reimplantatie halsvaten

UMC St Radboud

Dissectie : interventie

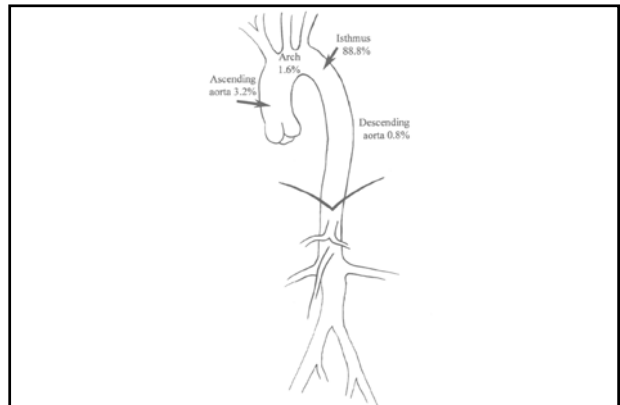
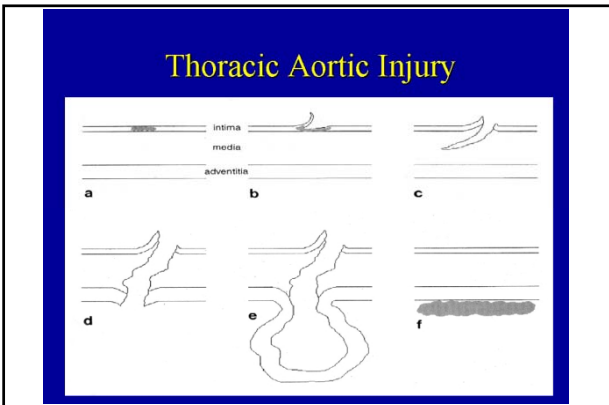
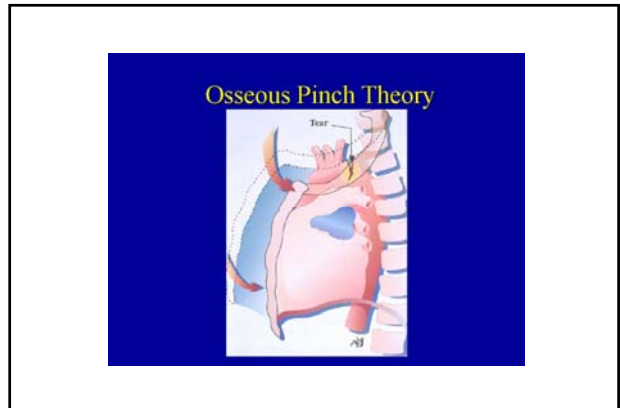
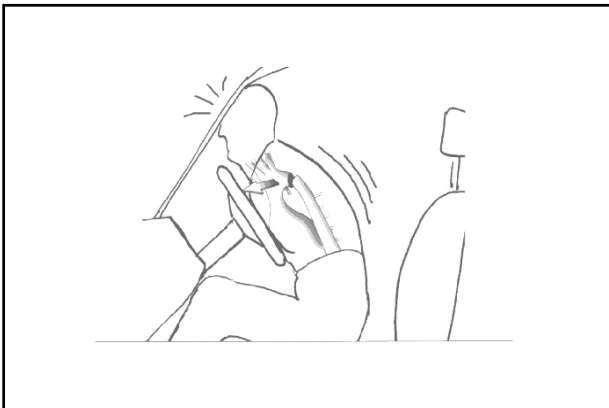- Stent
 - Aorta desendens/abdominaal
- Operatie
 - Vervanging:
 - Supracoronaire ascendensvervanging
 - Klepsparende wortelvervanging : Yacoub, David
 - Klepvervanging : Bentall
 - Boog : reimplantatie halsvaten

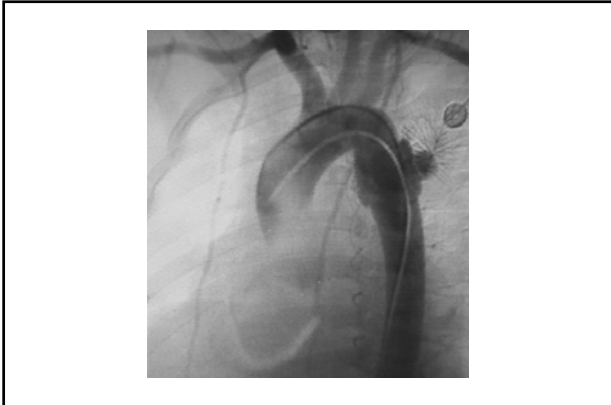


AORTA-RUPTUUR

Ruptuur

- Scheur binnenwand circulair, adventitia intact
 - Voorkeur: tpv ligamentum Botalli, ascendens, diafragma
- Oorzaken
 - Deceleratie-trauma : auto-gordel/stuur
- Risico's
 - (ver)bloeding: intrathoracaal






UMC St Radboud

Ruptuur : interventie

- Stent
- Ascendens: operatie zoals bij dissectie



UMC St Radboud